

b. A second black-billed specimen, purchased Sept. 25, 1876. This bird, when in immature and dirty plumage, on its first arrival, was wrongly referred to *P. schisticeps*, of which species we have never received living specimens.

c. A bird with the upper mandible red, and therefore, I suppose, male, brought from Muttra, North-west Provinces, and presented Feb. 21, 1878, by Mrs. Barthorp.

Of the allied form of Java and Borneo (*P. javanicus*<sup>1</sup>) we have at present no specimens in the Collection.

#### 6. CAICA XANTHOMERA. (Plate XXVIII.)

*Caica xanthomeria*, Selater, P. Z. S. 1857, p. 266.

*Psittacus xanthomerius*, Gray, List of Psitt. p. 73.

*Caica xanthomera*, Sel. P. Z. S. 1877, p. 419.

*Pionius xanthomerus*, Finsch, Papag. ii. p. 437.

Of this beautiful Parrot we received two living examples from Yquitos, on the Peruvian Amazons, in 1877, as already recorded. One of these is dead; but the other is now in fine plumage, as the accompanying sketch by Mr. Smit (Plate XXVIII.) will show.

Besides the type in the British Museum, from the Rio Javari (*Bates*), and a single example obtained alive by Natterer on the Madeira (Pelz. Orn. Bras. p. 264), our specimens are, I believe, the only ones known of this species.

#### 4. Notes on the Visceral Anatomy of the Tupaia of Burmah (*Tupaia belangeri*). By A. H. GARROD, M.A., F.R.S., Prosector to the Society.

[Received March 5, 1879.]

On February 8th, 1875, the Society received as a present from the Hon. Ashley Eden, C.S.I., a male Burmese specimen of *Tupaia belangeri*, which died, without any perceptible organic lesion, on December 18th, 1876.

Not much is known of the anatomy of the Tupaiidæ, the most important account of the viscera with which I am acquainted being that by Dr. Cantor on *Tupaia ferruginea*<sup>2</sup>.

Subjoined are the notes on the anatomy of the Society's specimen of *T. belangeri*.

The parotid and submaxillary glands are of about equal size, flattened and subcircular, a little less than half an inch in diameter, the duct of the former coursing superficially near the lower border of the powerful masseter muscle. The duct of the latter opens

<sup>1</sup> I cannot agree with Dr. Finsch's transfer of the name *alexandri* (Linn.) from the bird usually so called (i. e. *eupatrius*, Finsch) to the present species, for which the first name properly applicable seems to be *javanicus* of Osbeck, given in J. R. Forster's translation of Osbeck's Voyage to China, &c., vol. i. p. 156 (1781).

<sup>2</sup> Journ. Asiatic Soc. of Bengal vol. xv. 1846, p. 189.

by the side of its companion, at the tip of a small and slender pointed papilla situated just behind the symphysis of the lower jaw. The sublingual glands form a linear chain along the floor of the mouth.

The tongue, which is rounded at its tip, is 1·3 inch in length and ·35 inch broad, having its margins nearly parallel. Its upper surface is covered with filiform papillæ, among which are scattered papillæ fungiformes, very much in the same proportion as in the Ruminantia. There are three conspicuous circumvallate papillæ, arranged in the usual V-shaped manner.

A rudimentary unfringed sublingua exists, which is lanceolate in contour, just free at its margins, and with a strongly marked median raphé. It much resembles the same structure in *Cheiromys*<sup>1</sup>. Dr. Cantor says of the same organ in *Tupaia ferruginea*<sup>2</sup> that "on the lower surface of the tongue the frænum is continued to within a short distance of the apex, in a raised line, on either side of which the skin is thickened, fringed at the edges, and thus presenting a rudimentary sublingual appendage, somewhat similar to that observed in *Nycticebus tardigradus*, though in *Tupaia ferruginea* the fringes of the margin only are free, the rest being attached to the tongue, but easily detached by a knife."

The palate is transversely grooved, presenting upon its surface seven strong curved ridges, convex forward, and a small median incisor pad at its anterior end. The soft palate is smooth and lengthy, with no indication of the existence of a uvula.

The œsophagus has no free course in the abdominal cavity, being embraced by the diaphragm quite close to the cardiac orifice of the stomach.

The stomach is subglobose, with the cardiac and pyloric extremities approximate. When laid out flat its circumference is 6·2 inches, the interval between the axis of the œsophageal tube and that of the commencing duodenum being 0·9 inch. The squamous epithelium of the œsophagus does not enter the stomach, but ceases at its orifice, as in man. The gastric walls are simple, except that there are somewhat larger glands, in patches, on the anterior (ventral) surface.

The liver has no umbilical fissure, whilst both lateral fissures are strongly marked. There is a cystic fissure, at the bottom of which the fundus of the gall-bladder reaches the diaphragmatic surface of the organ. The *left lateral*, with its irregular inner margin, is the largest of the lobes; next comes the *right central*, on the visceral surface of which the imbedded gall-bladder lies diagonally. The *right lateral* lobe is slightly larger than the left central, and the caudate lobe but little smaller, whilst the Spigelian is a small sub-circular mass of hepatic tissue supported on a very slender stem. The bile and pancreatic ducts open together into the duodenum half an inch from the pylorus.

The walls of the intestines are thin. The small intestine is 29·25

<sup>1</sup> Owen, Trans. Zool. Soc. vol. v. pl. 24. figs. 8 & 9.

<sup>2</sup> Journ. Asiatic Soc. Bengal, 1846, p. 189, vol. xv.

inches in length, and 0·8 inch in circumference. The large intestine measures just over 3 inches, the conical and blunt-tipped cæcum not exceeding 0·7 inch in length. In Dr. Cantor's specimen of *Tupaia ferruginea* the small intestine is longer, reaching 40 inches. The mesenteric arteries form loops before they finally distribute.

The kidneys are smooth, with a single calyx. The testes appear large proportionately, the particularly big epididymis alone descending into the rudimentary scrotum. The prostate is bilobed, Cowper's glands being of fair size. The glans penis is elongately filiformly conical, and terminally a little blunted.

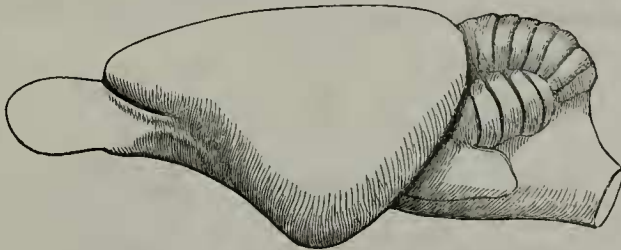
The aortic arch divides as in man, giving off a right innominate, a left carotid, and a left subclavian. There are two independent innominate veins, right and left.

The lungs are deeply divided into three main lobes on each side, whilst on the right the extra azygos triangular lobe is also found, not so large as any of the others.

Through the kindness of our President, I have had the opportunity of dissecting a female specimen of *Tupaia tana*, where there is a feebly developed sublingua, a less globose stomach, a lengthy thin-walled small intestine, *no trace of a cæcum*, and a thick-walled large intestine 3·25 inches long, quite easily distinguishable as such. The caudate lobe of the liver is much larger proportionately than in *T. belangeri*. In that there is no umbilical fissure, whilst that of the gall-bladder is very deep, the two species agree.

Dr. Günther has also permitted me to eviscerate a Bornean specimen of *Tupaia splendidula* in the National Collection. Its liver is constructed on a plan identical with that of the two other species, the left lateral lobe being much the largest, the umbilical fissure

Fig. 1.



Brain of *Tupaia belangeri*; lateral aspect.

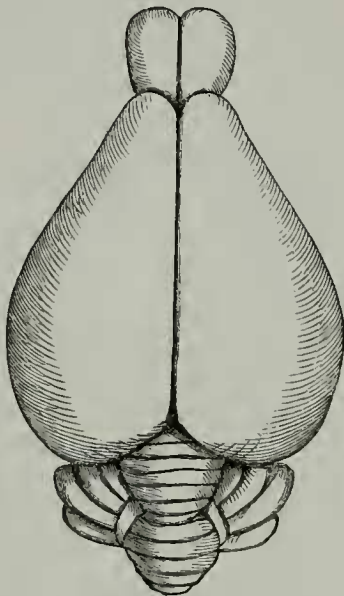
nearly obsolete, the cystic fissure deep, and the Spigelian lobe bifid. The caudate lobe, however, is long and narrow. The colon was very much distended, and with it the cæcum, so that the ileo-cæcal valve appeared to be situated at the side of the dilated colon, near to the blind extremity. If there had been no enlargement I should infer, from inspection, that the cæcum is normally less than half an inch in length.

The brain of *Tupaia belangeri* is smooth on its surface, and otherwise much resembles that of *Solenodon*<sup>1</sup>, *Rhynchocyon*, *Petro-*

<sup>1</sup> "Ueber die Säugethiergattung *Solenodon*," pl. ii., *Abhandlungen der k. Akad. der Wiss. zu Berlin*.

*dromus*, and *Macroscelides*, as figured by Dr. Peters<sup>1</sup>. It is broadest a little behind its middle, from which it narrows gradually in front, more rapidly behind, so as to be pyriform in general outline when

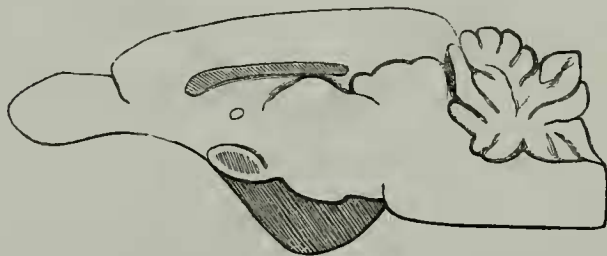
Fig. 2.



Brain of *Tupaia belangeri*; superior aspect.

seen from above. No trace of any convolutions can be detected. The olfactory lobes are considerable in size, longer than broad. Each hemisphere is very slightly convex from before backwards, its

Fig. 3.



Brain of *Tupaia belangeri*; mid-longitudinal section.

outline forming the base of the triangular side view of the organ, the two other sides of which are of nearly equal length, so that its deepest part is at about its middle.

The corpus callosum is thin and nearly straight. It continues forward to within one sixth of the length of the hemisphere from its

<sup>1</sup> Reise nach Mossambique, 1852, pl. xxiv. figs. 10, 12, 13.

